

Long-Term Rare Complication of Rhinoplasty: Nasal Dorsum Cyst

Ergin Eroğlu , Serdar Özer , Tevfik Metin Önerci 

Department of Otorhinolaryngology, Hacettepe University School of Medicine, Ankara, Turkey

Abstract

Dorsal cyst, one of the long-term complications of rhinoplasty, is rare, and very few cases have been reported in the literature. These cysts are mostly mucous cysts and are caused by the transplantation of the mucosa into the ectopic subcutaneous structures or by different materials that cause a foreign body reaction. Here, we present a case of a 28-year-old female patient with a nasal dorsal cyst that developed 10 years after a primary rhinoplasty. Since the cyst, which grew progressively over time, caused deformity and deformity in the nasal roof, it was totally excised and revision rhinoplasty was performed. No complications were seen during and after the surgery.

Keywords: rhinoplasty, nasal cyst, long term complication

INTRODUCTION

Nasal dorsal cysts are rarely observed in nasal masses. It is mostly in a dermoid cyst structure and is congenital. While dermoid cysts contain ectodermal and mesodermal structures, they may be associated with intranasal and intracranial structures. Apart from congenital cysts, acquired cysts can also be seen. These cysts usually appear as swellings that develop in the nasal dorsum overtime after a surgical trauma. These cysts are mostly mucous cysts, and their formation is blamed for the sowing of the mucosa to the structures under the ectopic skin.¹ In addition, foreign body reactions to the materials used in the nasal dorsum may also cause nasal cysts.²

Rhinoplasty is one of the most frequently performed surgical procedures today. Many early and late complications can be seen. Irregularities in the nasal dorsum after surgery can be caused by cartilage and bone structures forming the nasal skeleton roof, as well as different pathologies such as cysts and soft tissue edema. One of them is nasal dorsal cysts. Cysts that develop after rhinoplasty are usually of ectodermal origin.³ Cysts seen after rhinoplasty can be seen in different areas of the nose such as radix, tip, and dorsum.^{4,5}

Here, we share a case in which a cyst developed in the nasal dorsum after a rhinoplasty and caused a deformity in the shape of the nose.

CASE PRESENTATION

A 28-year-old female patient was admitted to our clinic with complaints of a mass on the nasal dorsum and nasal congestion. The patient, whose family history was unremarkable, has a history of severe nasal trauma at 5 years old. She had a closed technical rhinoplasty surgery 10 years ago due to her esthetic concerns. The patient, who did not have any problems in the postoperative period, had a slight shape change in the nose over time, but it was not in an uncomfortable condition. In the imaging performed for neck pain 3 years ago, it was determined that there was a nasal cyst in the cross-sectional area. Over time, the cyst grew progressively, and it also occasionally grew and shrunk.

On physical examination, a mobile 2 × 2 cm mass with a mild fluctuation was palpated mostly on the left side of the nose (Figure 1). In nasal endoscopy, the septum was deviated anteriorly to the left posteriorly to the right, the right inferior turbinate was hypertrophied, and there was synechia between the septum and inferior turbinate on the left anterior. In addition, nasal type drooping and pushing to the right, and asymmetry in the alar cartilages were present. Computed tomography showed a mass that caused remodeling in the bone extending from the nasal dorsum to the tip, while magnetic resonance imaging confirmed the cystic nature of this mass (Figure 2).

The patient underwent open technique rhinoplasty, nasal synechia opening, and cyst excision. When the elevation was completed by entering through a columellar incision, the cyst was dropped on it. It was observed that the cyst

Cite this article as:

Eroğlu E, Özer S, Önerci TM. Long-Term Rare Complication of Rhinoplasty: Nasal Dorsum Cyst. *Eur J Rhinol Allergy* 2021;4(2):68-70.

Address for Correspondence:

Ergin Eroğlu

E-mail:
drergineroglu@gmail.com

Received: August 12, 2021

Accepted: August 16, 2021

DOI: 10.5152/ejra.2021.21040

© Author(s) - Available online at
www.eurjrhinol.org

Content of this journal is licensed under a Creative Commons Attribution-NonCommercial 4.0 International License.



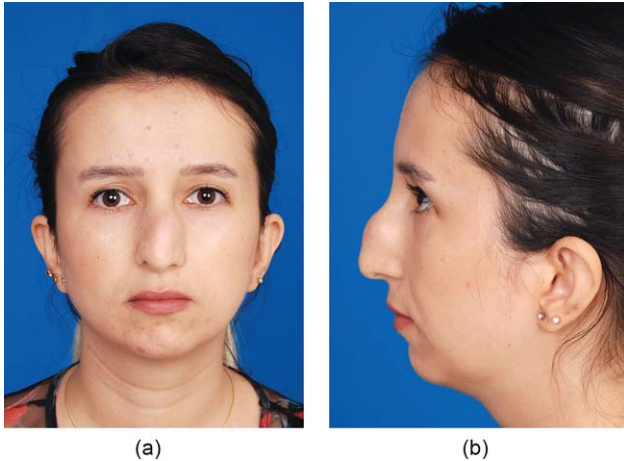


Figure 1. Preoperative photographs show a cystic mass in the nasal dorsum that has caused asymmetry in the nose.

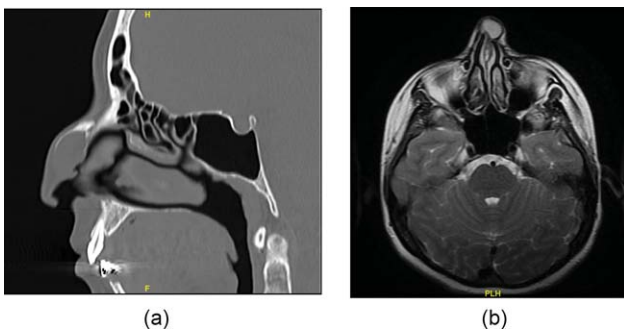


Figure 2. A cystic mass remodeling in the bone is seen in computed tomography (a) and magnetic resonance imaging (b).

was sitting on the septum, elevating the upper lateral cartilages and the nasal bone on the left (Figure 3). In addition, the dorsal part of the right upper lateral cartilage was found to be defective due to surgery. The cyst was dissected from the surrounding tissues and removed. Total septal reconstruction was performed to form the nasal septum L strut. Nasal dorsal structures were reconstructed with cartilage grafts.

When the cyst material was examined macroscopically, it was approximately 2 × 2 × 1 cm in size, and its contents were yellow-green viscous.

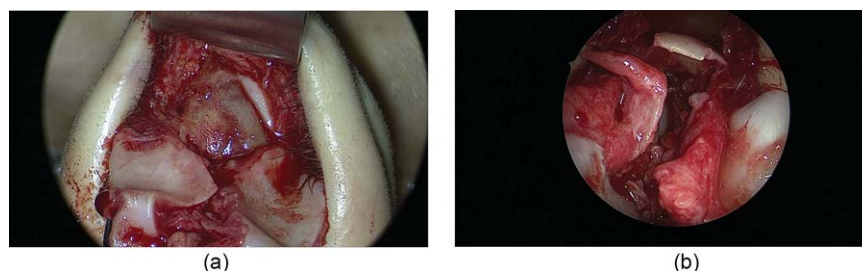


Figure 3. In. the intraoperative image of the cyst, it is seen that it sits on the septum and elevates the upper lateral cartilages (a) and the cyst area under the nasal bone after it is excised (b).

After the microscopic examination, foreign body giant cell reaction, benign cystic structure, and active chronic inflammation were reported in the final pathology.

DISCUSSION

Rhinoplasty is a frequently performed surgery recently. Many complications have been described in rhinoplasty, in which patient and surgeon satisfactions are at the forefront. Tissue edema, periorbital ecchymosis, infective events, and skin necrosis are early complications. The most important long-term complications are postoperative deformities and constitute 5-15% of all cases.⁶ Cyst formation is a rare long-term complication.

In patients presenting with a mass in the nasal dorsum, first of all, it is necessary to consider the differential diagnosis, make the correct diagnosis, and share the treatment alternatives with the patient. In this context, encephalocele, glioma, dermoid cyst, osteoma, lipoma, neoplastic lesions, granulomatous diseases (microscopic polyangiitis, sarcoidosis, and rhinoscleroma), and infectious diseases (fungal, syphilis, and tuberculosis) should be considered in the differential diagnosis.⁷

Nasal dorsum cyst may occur by different mechanisms. Considering the literature, ectopic implantation of the mucosa during surgery, herniation of the mucosa through intranasal incisions, and inadequate cleaning of epithelial remnants are among the theories.⁸ Other possible causes are implant materials that cause foreign body reactions and fillers used for augmentation.⁹ In our case, although it is not certain when the location of the cyst and the pathology result is taken into account and evaluated, it is thought that a material used in dorsal augmentation or a foreign body that was forgotten during the first surgery caused the cyst formation.

The treatment of nasal dorsum cysts that develop after rhinoplasty is a complete resection of the cyst. The surgical approach may vary depending on the location and size of the cyst, and additional complaints of the patient. Considering the previously shared cases, resections were mostly performed with an incision made on the cyst.¹⁰ However, we completed our surgery with the open technique rhinoplasty approach by entering through a columellar incision, as the patient's esthetic concerns continued, and the cyst sizes were greater than the cases reported in the literature. Another issue is the need for grafts used in the reconstruction. Depending on the erosion and remodeling of the cyst, graft materials can be taken from the auricle or rib. In our case, graft materials taken from the nasal septum were sufficient for reconstruction.

In conclusion, when examining the literature, the dorsal nasal cyst formation is a rare complication that develops late post-rhinoplasty.^{7,9,11-14} The most important way to prevent this complication is a careful dissection

before osteotomy and hump resection, the removal of epithelial remnants from graft materials, and not using materials for augmentation that may cause foreign body reaction. With the increasing surgical experience, such complications will decrease.

Informed Consent: Written informed consent was obtained from all participants who participated in this study.

Peer-review: Externally peer-reviewed.

Author Contributions: Concept - E.E.; Design - E.E.; Supervision - M.Ö., S.Ö.; Resource - S.Ö.; Materials - E.E., S.Ö.; Data Collection and/or Processing - E.E.; Analysis and/or Interpretation - S.Ö., M.Ö., E.E.; Literature Search - E.E.; Writing - E.E., S.Ö.; Critical Reviews - M.Ö., S.Ö., E.E.

Conflict of Interest: The authors have no conflicts of interest to declare.

Financial Disclosure: The authors declared that this study has received no financial support.

REFERENCES

1. Kumral L, Uyar Y, Yildirim G, et al. The development of dorsal nasal cyst formation after rhinoplasty and its reconstruction with Conchal cartilage. *Case Rep Otolaryngol.* 2014;2014:1-3. [\[CrossRef\]](#)
2. Pak MW, Chan ES, van Hasselt CA. Late complications of nasal augmentation using silicone implants. *J Laryngol Otol.* 1998;112(11):1074-1077. [\[Cross-Ref\]](#)
3. Hughes GB, Sharpino G, Tucker HM. Management of the congenital midline nasal mass: A review. *Head Neck Surg.* 1980;2:222-233. [\[CrossRef\]](#)
4. Riedel F, Bersch C, Ormann KH. Dorsal nasal mass formation: Postrhinoplasty cys. *HNO.* 2007;55(6):472-474. [\[CrossRef\]](#)
5. Raine C, Williamson SLH, McLean NR. Mucous cyst of the alar base: A rare complication following rhinoplasty. *Br J Plast Surg.* 2003;56(2):176-177. [\[CrossRef\]](#)
6. Rettinger G. Risks and complications in rhinoplasty. *GMS Curr Top Otorhinolaryngol Head Neck Surg.* 2007;6:1-14.
7. Unlu CE, Saylam G, Korkmaz H, et al. Nasal dorsal mucous cyst formation: A rare and preventable complication of rhinoplasty. *Kulak Burun Bogaz Ihtisas Dergisi.* 2011;21(5):294-297. [\[CrossRef\]](#)
8. Pausch NC, Bertolini J, Hemprich A, et al. Inclusion mucous cysts of the nose: A late complication after septorhinoplasty in two cleft lip patients. *Cleft Palate Craniofac J.* 2010;47(6):668-672. [\[CrossRef\]](#)
9. Chang DY, Jin HR. Foreign body inclusion cyst of the nasal radix after augmentation rhinoplasty Y. *J Korean Med Sci.* 2008;23(6):1109-1112. [\[CrossRef\]](#)
10. Giacomini PG, Topazio D, Di Mauro R, et al. Unusual postrhinoplasty complication: Nasal dorsum cyst. *Case Rep Otolaryngol.* 2014;2014:1-4. [\[CrossRef\]](#)
11. Kotzur A, Mucous GW. Cyst—A postrhinoplasty complication: Outcome and prevention. *Plast Reconstr Surg.* 1997;100(2):520-524. [\[CrossRef\]](#)
12. Harley EH, Erdman JP. Dorsal nasal cyst formation. A rare complication of cosmetic rhinoplasty. *Arch Otolaryngol Head Neck Surg.* 1990;116(1):105-106. [\[CrossRef\]](#)
13. Romo T, Rizk SS, Suh GD. Mucous cyst formation after rhinoplasty. *Arch Fac Plast Surg.* 1999;1(3):208-211. [\[CrossRef\]](#)
14. Struijs B, Bauwens LJJM. Post-rhinoplasty mucous cyst formation of the nasal dorsum. *B-ENT.* 2010;6(4):295-298.