

# Bilateral Nasoalveolar Cyst Causing Nasal Obstruction

Mesut Tozar<sup>1</sup>, Gökçe Şimşek<sup>1</sup>, Burak Mustafa Taş<sup>1</sup>, Birsen Ünal Daphan<sup>2</sup>, Rahmi Kılıç<sup>1</sup>

<sup>1</sup>Department of Otolaryngology, Kırıkkale University School of Medicine Hospital, Kırıkkale, Turkey

<sup>2</sup>Department of Radiology, Kırıkkale University School of Medicine Hospital, Kırıkkale, Turkey

## Abstract

Nasoalveolar cysts, non-odontogenic in origin, are soft-tissue lesions of the upper jaw, are derived from nasolacrimal canal epithelium, and are mostly unilateral but sometimes bilateral. Another theory about its etiology is that it occurs because of embryonic fissure cysts. These lesions are thought to be developmental. They can cause swelling and nasal obstruction in the upper lip, alar area, and palate. In this case report, we discuss the role of nasoalveolar cysts in nasal obstruction and how they can be bilateral. A 31-year-old female patient visited our clinic with complaints of nasal obstruction and swelling in front of the nose for 2 years. An anterior rhinoscopic examination revealed a mass and stenosis in both nasal vestibules. Computed tomography revealed a mass-like nasoalveolar cyst in the inferior alar region. Under general anesthesia, a 1-cm mass from the right side and a 2-cm mass from the left side were excised, which were pathologically confirmed as nasoalveolar cysts. Nasoalveolar lesions are rare and mostly unilateral. Bilateral nasoalveolar cysts should be considered in the differential diagnosis of nasal obstruction.

**Keywords:** Nasoalveolar cyst, nasal obstruction, nasolacrimal canal epithelium

## INTRODUCTION

Nasoalveolar cysts, which originate from the epithelial remnants of the nasolacrimal duct, are benign, developmental, non-odontogenic, soft-tissue lesions seen in the maxillary region. They are also called nasolabial or Kleinstadt's cysts. These cysts occur most commonly between the ages of 40 and 50 years (1). They are located in the submucosa and seen four times more frequently in women than in men. They are usually unilateral, with 10% of cases having been reported to be bilateral. The incidence of these cysts is 0.7% in overall jaw cysts, and they occur more frequently on the left side. They may remain asymptomatic or cause symptoms such as nasal obstruction, swelling in the alar region, and palatal mass or mass on the upper lip (2). These cysts are usually painless, but if infected, may cause pain and nasal discharge. They might be misdiagnosed as benign or malignant tumors, follicles, and odontogenic cysts such as periodontal or residual cysts. Here, we describe the role of nasoalveolar cysts in the etiology of nasal congestion and their bilateral nature in a patient.

## CASE REPORT

A 31-year-old female patient was admitted to our clinic with complaints of nasal congestion and painful nasofrontal swelling persistent for 2 years. An anterior rhinoscopic examination demonstrated a mass and a mass-related stenosis at the entrance of both nasal vestibules. Computed tomography demonstrated a bilateral, smooth-walled mass compatible with nasoalveolar cysts in the inferior alar region. The patient underwent surgery under general anesthesia, and cysts of 1 and 2 cm were completely excised from the right and left sides, respectively. The pathology report was also compatible with the diagnosis of bilateral nasoalveolar cysts.

Written informed consent was obtained from patient.

## DISCUSSION

Nasoalveolar cysts are considered to be congenital, but can grow developmentally. There are two theories regarding their formation. The first theory holds that the cysts arise from the remnants of the nasolacrimal duct, and the other states that the cysts are embryonic fissure cysts. When the cysts were first described, they were thought to originate from the remnants of the mucosal gland (3). Later, Kleinstadt postulated that the cysts arose from the tissue remaining between the embryonic nasal mucosa, maxillary process, and lateral-medial nasal process. Nasoalveolar cysts usually cause no symptoms and are located in the alar region. As the size of the cyst increases, it becomes symptom-

**Cite this article as:** Tozar M, Şimşek G, Taş BM, Ünal Daphan B, Kılıç R. Bilateral Nasoalveolar Cyst Causing Nasal Obstruction. Eur J Rhinol Allergy 2018; 1: 54-5.

**Address for Correspondence:** Mesut Tozar

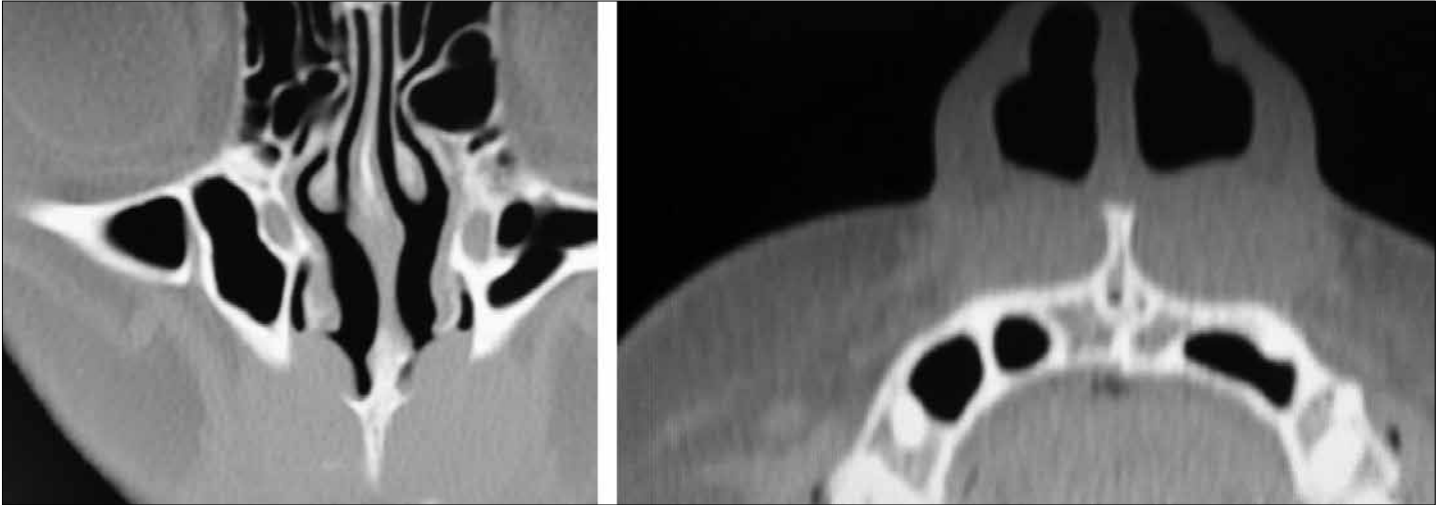
**E-mail:** mesut\_tozar@hotmail.com

**Received:** 26.01.2018

**Accepted:** 09.05.2018

**DOI:** 10.5152/ejra.2018.59257

©Copyright 2018 by Turkish Rhinologic Society - Available online at [www.eurjrhinol.org](http://www.eurjrhinol.org)



**Figure 1.** On coronal and axial computed tomography sections of the paranasal sinuses, bilateral nasoalveolar cysts were observed

atic and causes swelling in the face and hard palate. Although it is considered benign, there has been a literature report on its association with malignancy (3).

Nasoalveolar cysts are soft-tissue masses usually located in the maxillary bone. Computed tomography used in diagnosis demonstrates the cyst and its relationship with the nasal and oral cavity (5). Magnetic resonance imaging may also be preferred in cases in which malignancy is suspected. Nasoalveolar cysts do not invade the surrounding bone tissues and hence do not cause destruction. However, long-term compression by the cyst may cause bone tissue erosion. In our case, computed tomography examination showed a bilateral, smooth-walled mass compatible with nasoalveolar cysts in the inferior alar region.

Surgical intervention for nasoalveolar cysts is performed via the sublabial approach (2, 3). Other treatment options include marsupialization via the transnasal approach, injections of sclerosing agents, or aspiration of the cyst content (2). Lee et al. compared the transnasal approach with the sublabial approach and found that transnasal endoscopic marsupialization was more advantageous than the sublabial approach in terms of cost, surgery time, and pain (7, 8). In conclusion, marsupialization via the transnasal endoscopic approach was found to be an advantageous and effective treatment method. In our case, we completely excised both cysts via the sublabial approach instead of marsupialization. The cysts were removed with blunt and slow dissection since the walls of the cysts were thin. The advantage of the sublabial approach is clear visualization of the pyriform aperture and complete removal of the cyst.

## CONCLUSION

Nasolabial cysts are rarely seen, but may lead to cosmetic issues and nasal congestion. Computed tomography is the most common imaging method used in its diagnosis and also details important information about the

cyst and its surrounding tissues. Endoscopic transnasal marsupialization is an alternative to the sublabial approach. Postoperative swelling, pain, and recurrence rates are similar between these two approaches.

**Informed Consent:** Written informed consent was obtained from patient.

**Peer-review:** Externally peer-reviewed.

**Author Contributions:** Concept - G.Ş.; Design - M.T.; Supervision - G.Ş.; Data Collection and/or Processing - M.T.; Analysis and/or Interpretation - B.Ü.D., R.K.; Literature Search - B.M.T.; Writing Manuscript - M.T.; Critical Review - G.Ş.

**Conflict of Interest:** The authors have no conflicts of interest to declare.

**Financial Disclosure:** The authors declared that this study has received no financial support.

## REFERENCES

1. el-Din K, el-Hamd AA. Nasolabial cyst: a report of eight cases and a review of the literature. *J Laryngol Otol* 1999; 113: 747-9.
2. Yuen HW, Julian CY, Samuel CL. Nasolabial cysts: clinical features, diagnosis, and treatment. *Br J Oral Maxillofac Surg* 2007; 45: 293-7. [\[CrossRef\]](#)
3. López-Ríos F, Lassaletta-Atienza L, Domingo-Carrasco C, Martínez-Tello FJ. Nasolabial cyst. Report of a case with extensive apocrine change. *Oral Surg Oral Med Oral Pathol Oral Radiol Endod* 1997; 84: 404-6. [\[CrossRef\]](#)
4. Aquilino RN, Bazzo VJ, Faria RJA, Eid NLM, Bóscolo FN. Nasolabial cyst: presentation of a clinical case with CT and MR images. *Braz J Otorhinolaryngol* 2008; 74: 467-71. [\[CrossRef\]](#)
5. Van Gerven L, Vander Poorten V, Jorissen M. Adenocarcinomas of the sinonasal tract: current opinion. *B-ENT* 2011; 7 (Suppl 17): 15-20.
6. Chao WC, Huang CC, Chang PH, Chen YL, Chen CW, Lee TJ. Management of nasolabial cysts by transnasal endoscopic marsupialization. *Arch Otolaryngol Head Neck Surg* 2009; 135: 932-5. [\[CrossRef\]](#)